




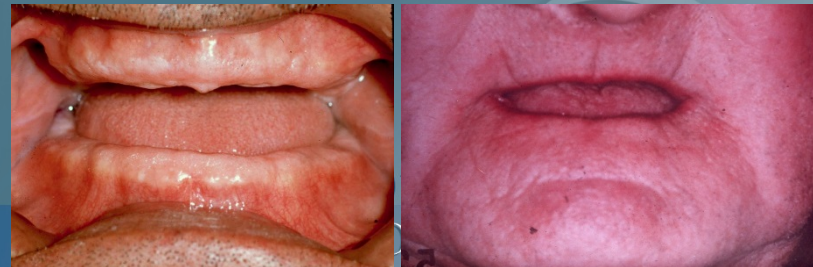
PASIENTEN MED TANNLØS KJEVE – ALTERNATIVE LØSNINGER

Asbjørn Jokstad

UiT Norges arktiske universitet

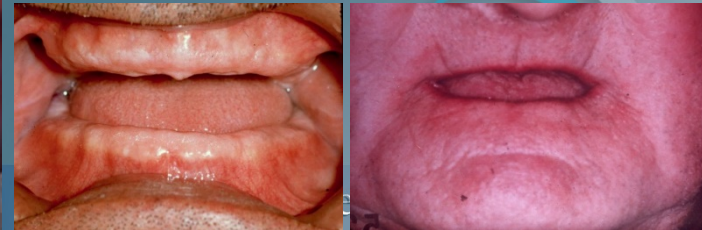
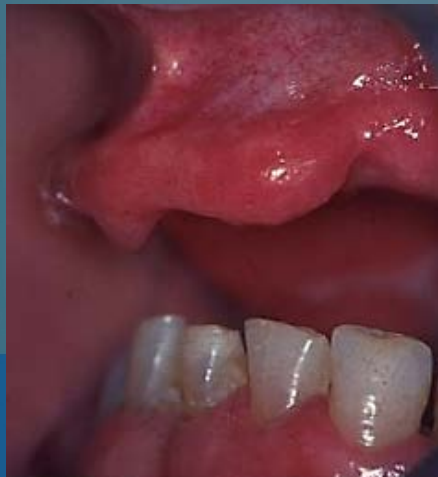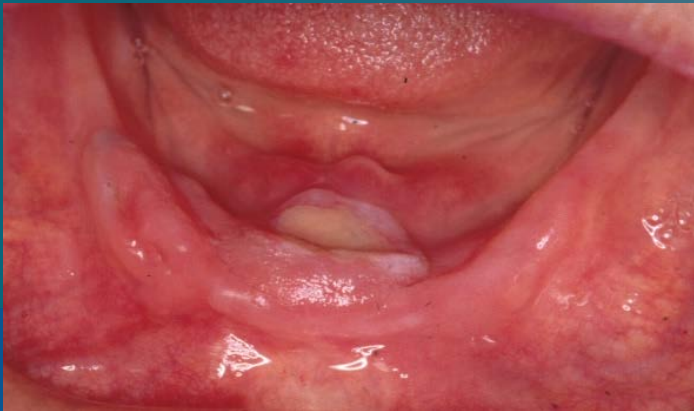Pasienten:

God helse, med tannløs kjeve



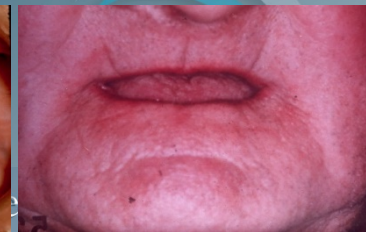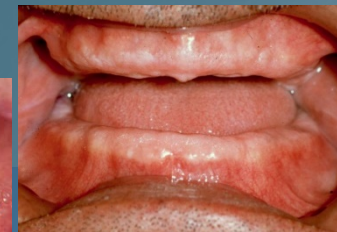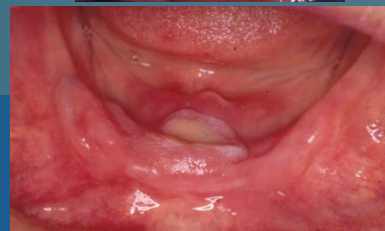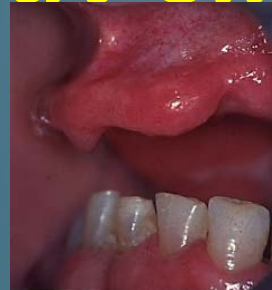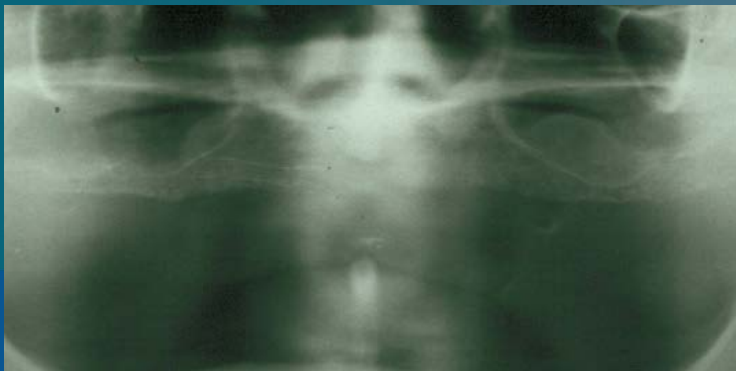Pasienten:

God helse, med tannløs kjeve,
karakterisert av *en atrofisk
kjevekam*



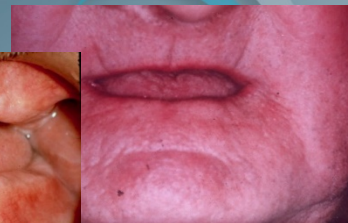
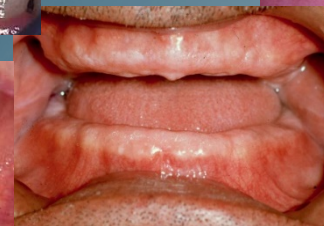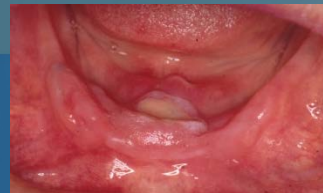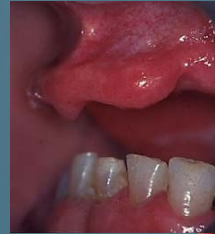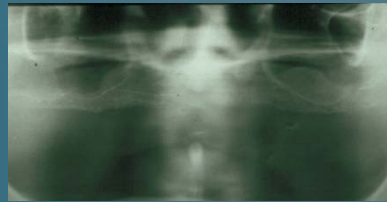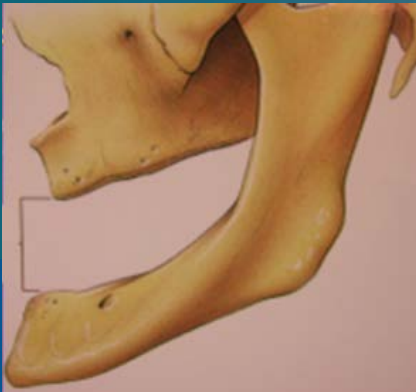Pasienten:

God helse, med tannløs kjeve,
karakterisert av en atrofisk
kjevekam og i overkjeven
pneumatisering av sinus



Pasienten:

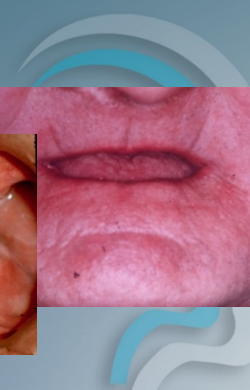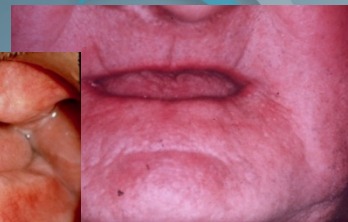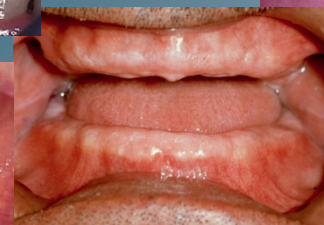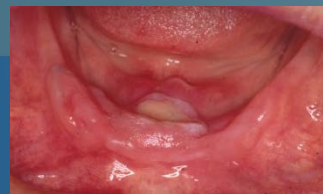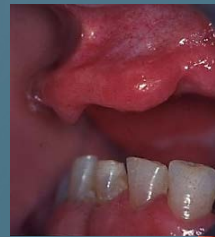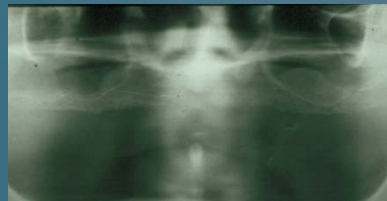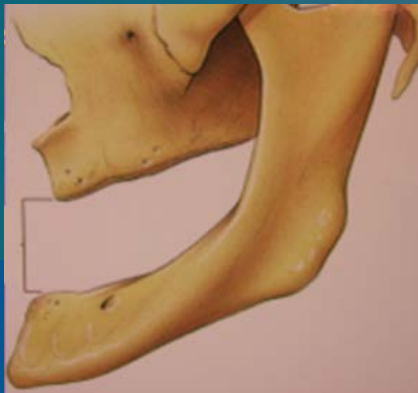God helse, med tannløs kjeve,
karakterisert av en atrofisk
kjevekam og i overkjeven
*pneumatisering av sinus og en
pseudo-klasse III kjeverelasjon*



eksempelvis,
Komorbiditet
Xerostomi
Nervesykdommer

Pasienten:

~~God~~ helse, med tannløs kjeve,
karakterisert av en atrofisk
kjevekam og i overkjeven
*pneumatisering av sinus og en
pseudo-klasse III kjeverelasjon*



System for inndeling av vanskelighetsgrad for behandling av fullt tannløse pasienter (dvs, begge kjever er tannløse)

Diagnostic criteria 1-4:

1. **Maxilla ridge morphology:** Anatomic features that to a varying degree resists horizontal and vertical movement of the denture base
2. **Maxillo-mandibular relationship:** Relates to the position of the artificial teeth to the residual ridge and to the opposing dentition
3. **Mandibular muscle attachments**
4. **Remaining bone height of mandible (proxy for inter-arch space) – 18-20 mm is minimum**

System for inndeling av vanskelighetsgrad for behandling av fullt tannløse pasienter (dvs, begge kjever er tannløse)

Diagnostic criteria 1-4:

1. **Maxilla ridge morphology:** Anatomic features that to a varying degree resists horizontal and vertical movement of the denture base
2. **Maxillo-mandibular relationship:** Relates to the position of the artificial teeth to the residual ridge and to the opposing dentition
3. **Mandibular muscle attachments**
4. **Remaining bone height of mandible** (proxy for inter-arch space) – 18-20 mm is minimum

I. Ideal eller minimally compromised: Most apt to be successfully treated of usual prosthodontic techniques with complete denture prosthesis

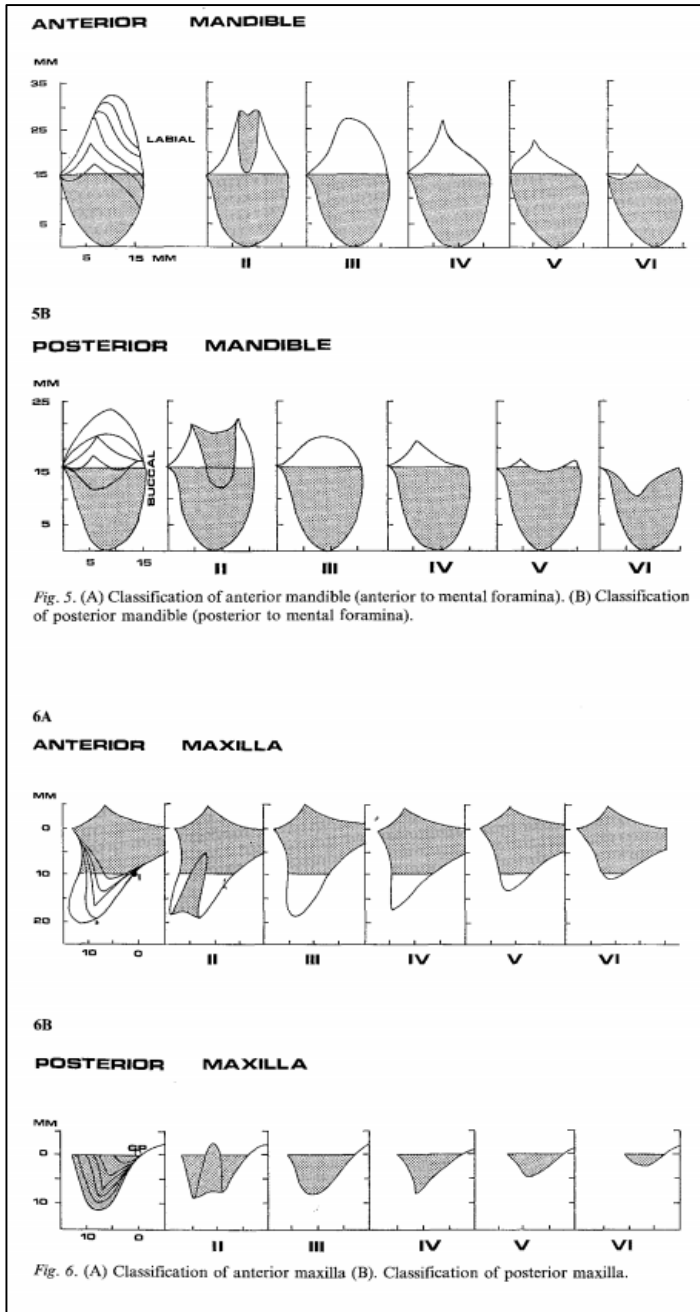
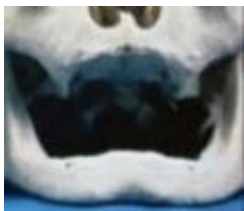
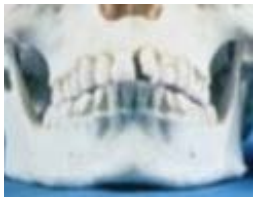II. Moderately compromised: Degradation of the denture supporting structures and in addition is characterized by the early onset of systemic disease interactions, localized soft tissue factors and patient management/lifestyle considerations

III. Substantially compromised: Surgical revision of denture supporting structures needed to allow for adequate prosthodontic function

IV. Severely compromised

Anatomi - bein

Cawood-Howell klassifisering



Klasse	Kjeve	Høyde	Bredde	Komm.
II				Post ekstraksjon
III	Avrundet	Adekvat (>10mm)	adekvat (>4mm)	*
IV	Skarp	Adekvat (>10mm)	mangelfull (< 4mm)	
V	Flat	Mangelfull (<10 mm)	mangelfull (< 4mm)	
VI	Ned-sunket			Noe tap av basalbein tydelig

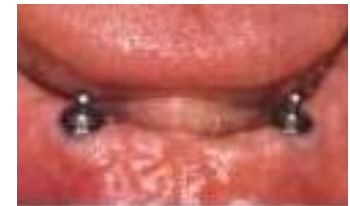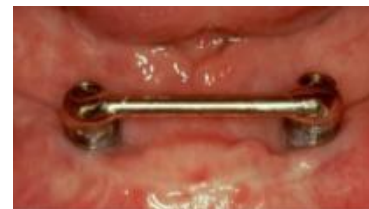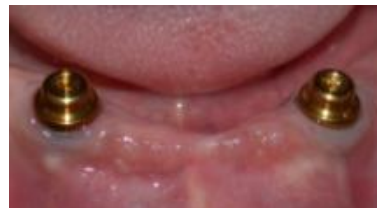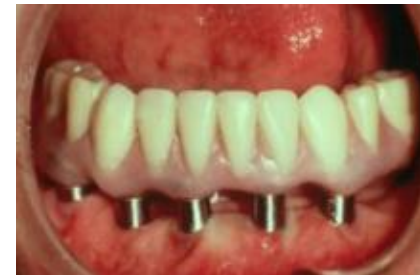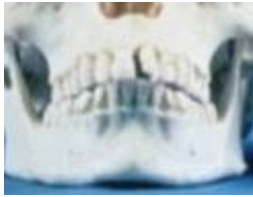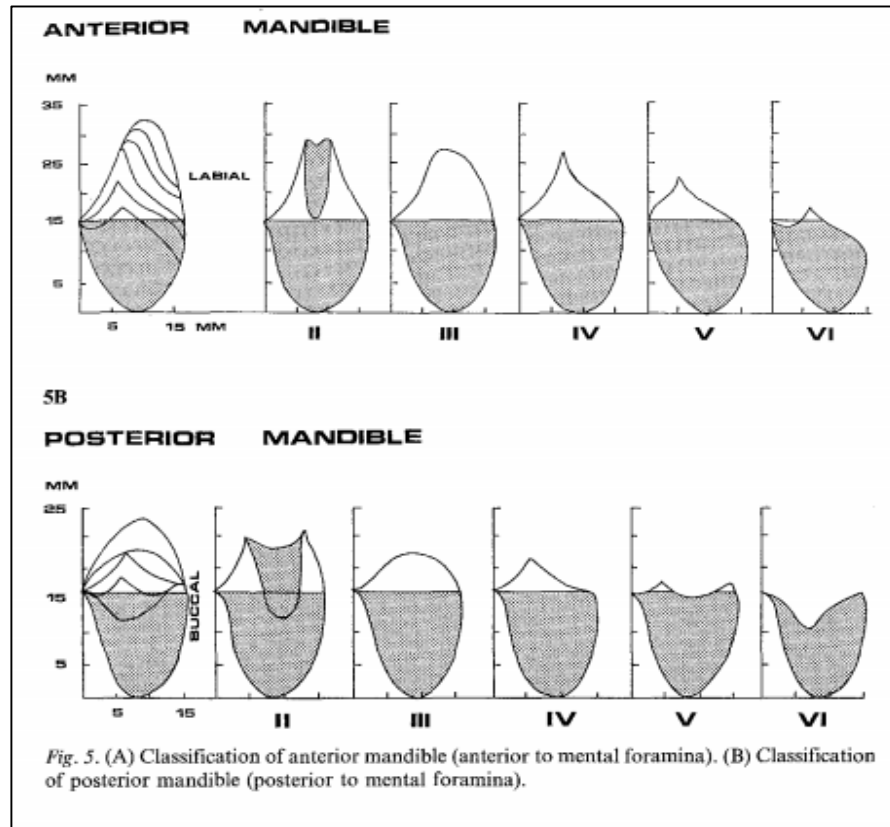
(* mm for høyde&bredde ikke angitt i originalartikkelen)

[A classification of the edentulous jaws.](#)

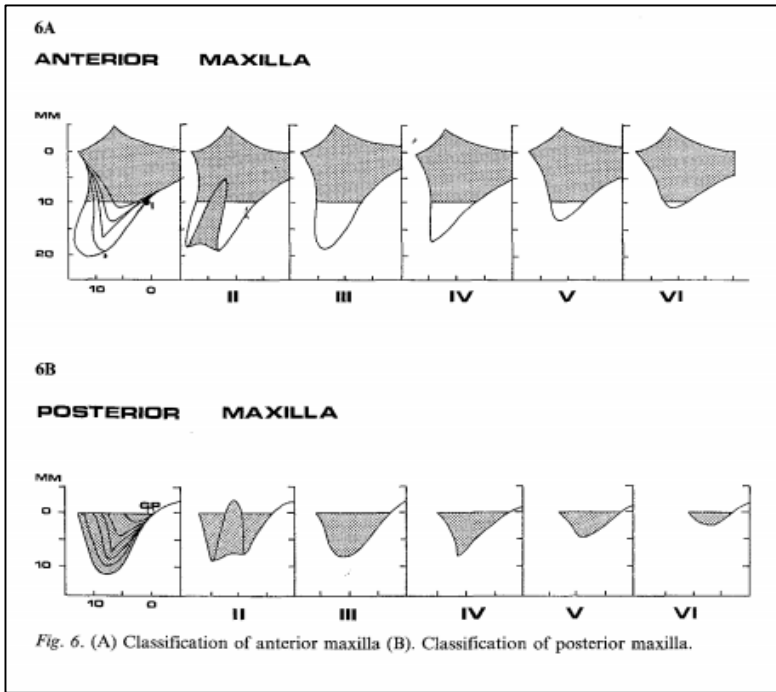
Cawood JI, Howell RA.

Int J Oral Maxillofac Surg. 1988 Aug;17(4):232-6.

Anatomi – bein, underkjeven



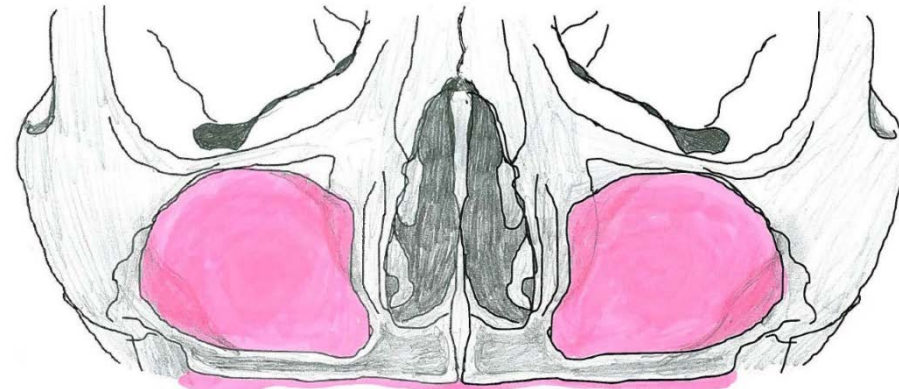
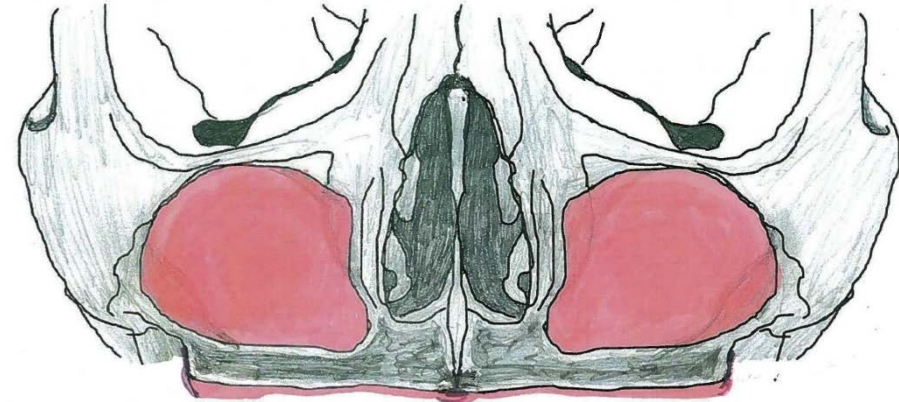
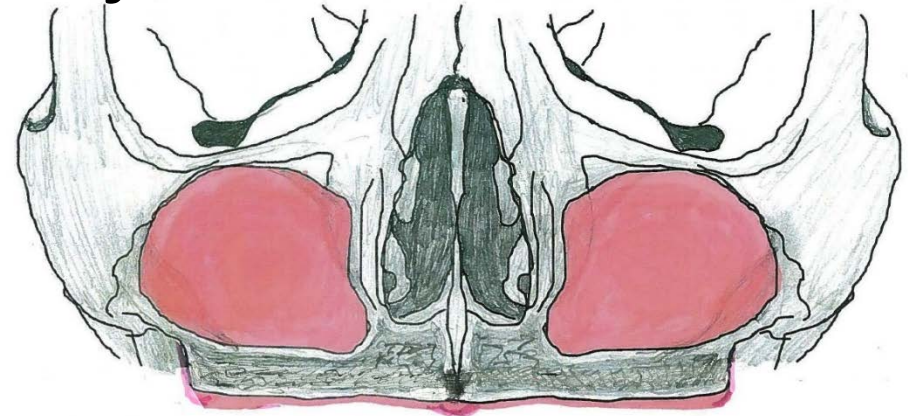
Anatomi – bein, overkjeven



[A classification of the edentulous jaws.](#)

Cawood JI, Howell RA.

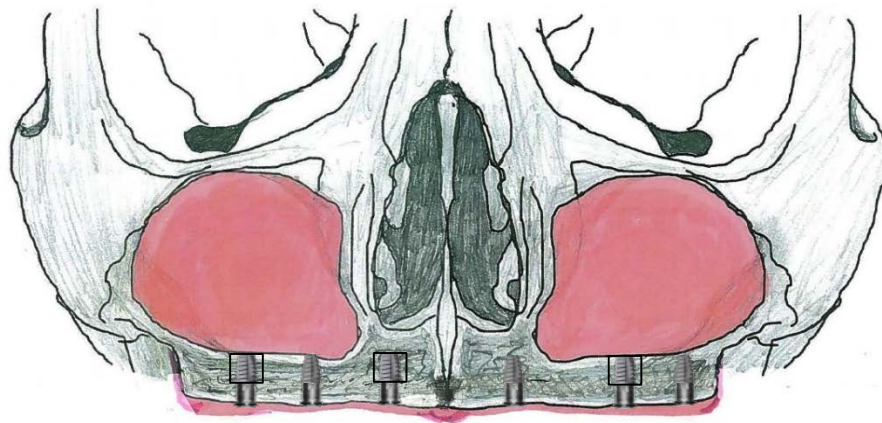
Int J Oral Maxillofac Surg. 1988 Aug;17(4):232-6.



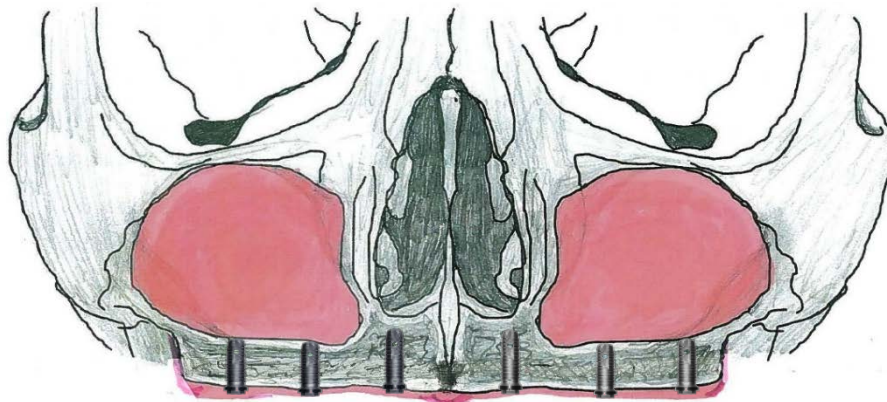
System for inndeling av vanskelighetsgrad for behandling av pasient med tannløs overkjeve med tannimplantat



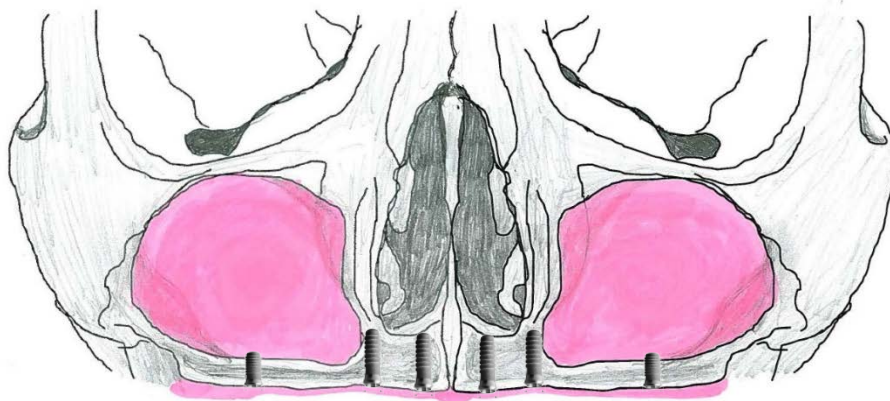
Group	Bone width of alveolar ridge	Interarch relation Vertical	Interarch relation Horizontal	Surgical approach
1	Adequate	Acceptable	Acceptable	Sinus floor elevation (SFE)
2	Inadequate	Acceptable		SFE and horizontal ridge bone augmentation Autogenous (horizontal) block graft (may be combined with a bone substitute material + a barrier membrane) Intraoral or extraoral donor site depending on the extent of atrophy
3	Adequate	Unfavorable	Acceptable	SFE and vertical ridge bone augmentation Autogenous (horizontal) block graft (may be combined with a bone material + a barrier membrane) Intraoral or extraoral donor site depending on the extent of atrophy
4		Unfavorable	Unfavorable	SFE procedure and horizontal/vertical ridge bone augmentation. Autogenous block graft (may be combined with a bone substitute material + a barrier membrane)



Implantater med to forskjellige skjæreprofiler (Brånemark™)



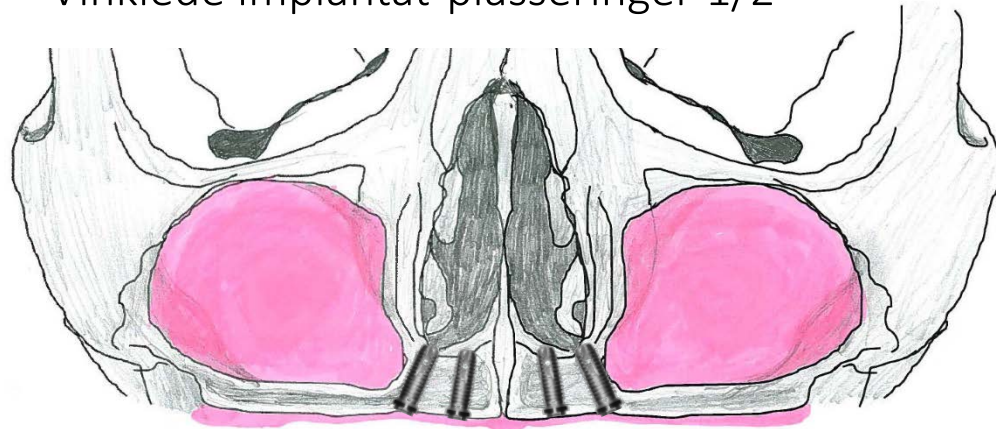
Forskjellige implantater (CoreVent™)



Korte implantater plassert i redusert bein distalt, med lengre implantater plassert anteriort (Cawood-Howell klasse IV) (Straumann™)

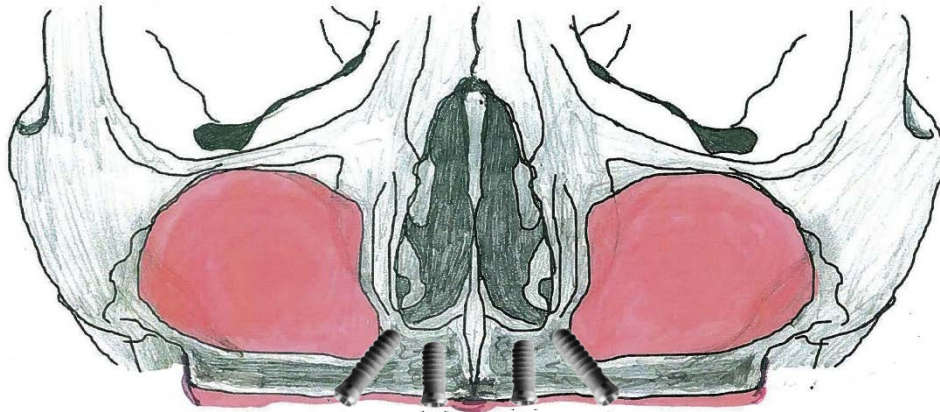4 x 10-14mm + 2 x 6mm distalt

Vinklede implantat-plasseringer 1/2



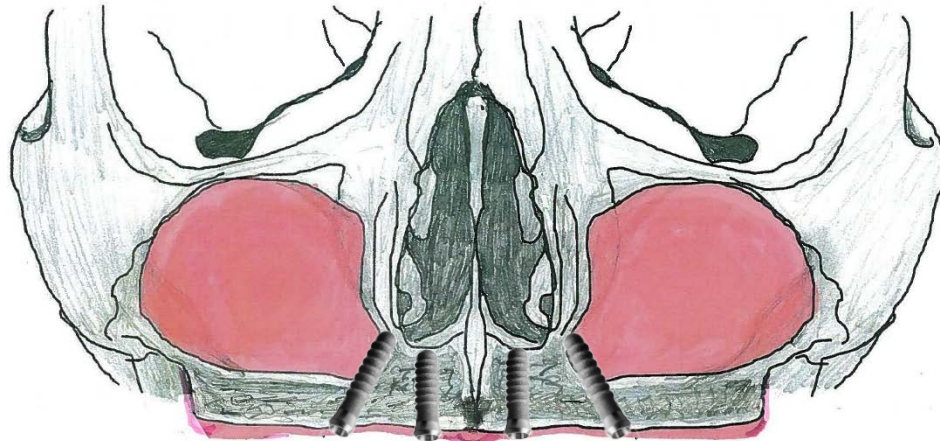
4 distalt vinklede implantater i en C-H klasse V/VI (Brånemark™)

2x 10mm + 2 x 14mm 45° tilt



2 aksiale og 2 30-45° distalt vinklede implantater (C-H klasse III/IV) (Replace™)

2x 10mm + 2 x 13-15mm 30-45° tilt

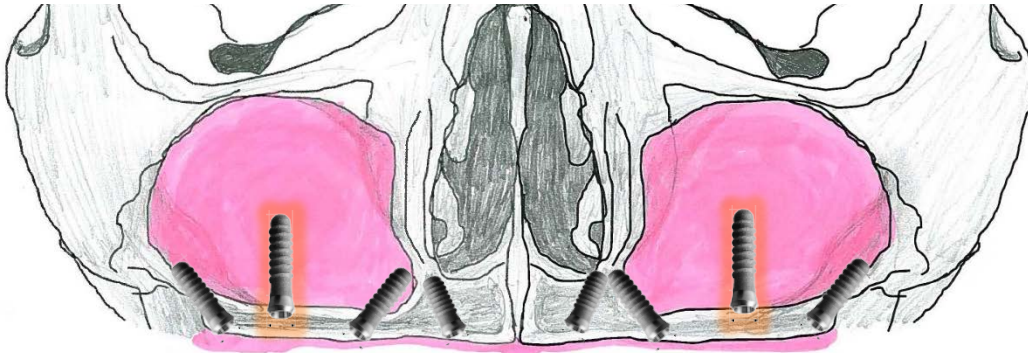


2 aksiale og 2 30° distalt vinklede "eksternhex" implantater plassert umiddelbart i ekstraksjonsalveoler (C-H klasse II) (Replace™)

2x 14mm + 2 x 18mm 30° tilt

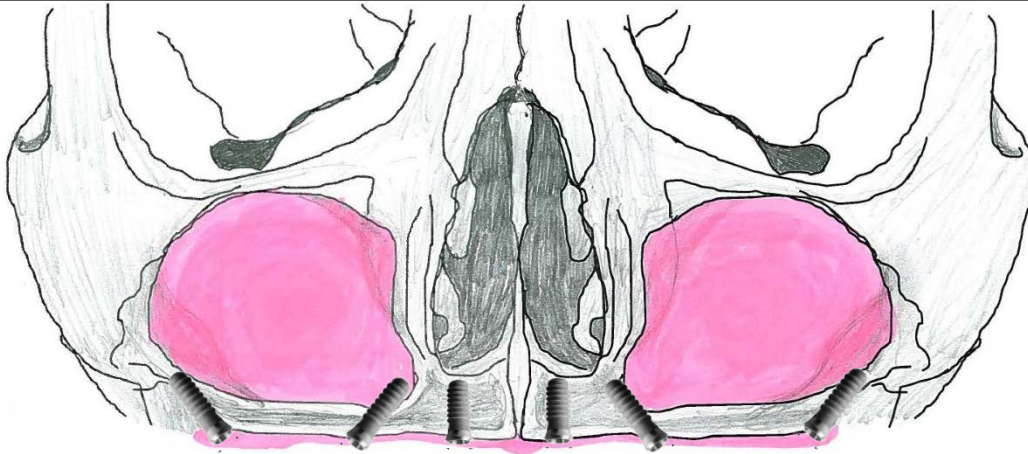Fra: Jokstad et al. IJOMI 2016

Vinklede implantat-plasseringer 2/2



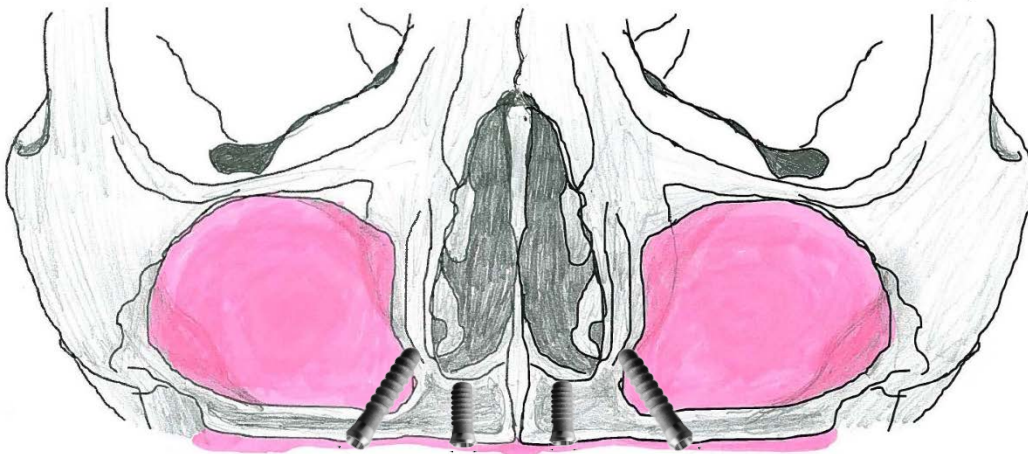2 distalt + 4 mesialt 25-30° vinklede + 2 implantater i ganen (Replace™)

2x 10mm 25-30° mes.tilt + 4 x 13mm 25-30° mes&dist.tilt + 2x 13mm i ganen



2 aksiale + 4 25-30° mesialt og distalt vinklede implantater (Replace™)

Poster. 2x 13mm 30-45° tilt + Medialt 2x 13mm 30-45° tilt, Aksial 2x10mm

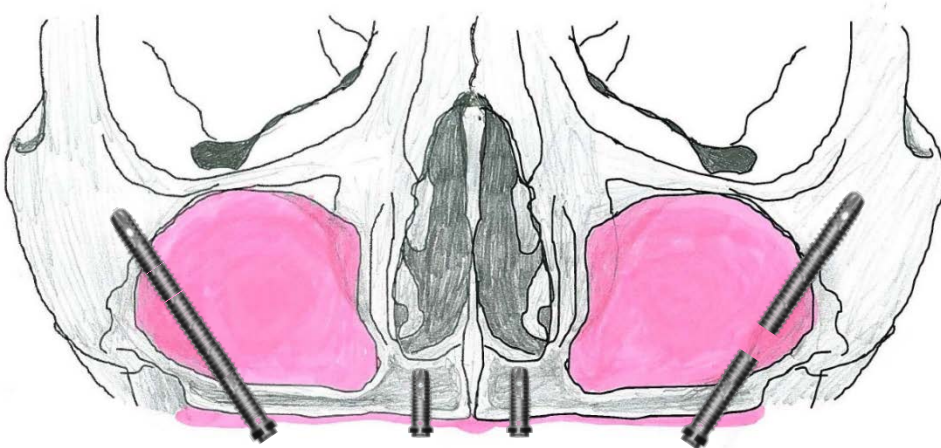


2 aksiale & 2 distalt vinklede implantater, gjennom sinus for fiksering i fire lag av kortikalt bein (Replace™) (All-on-four™)

2x 10mm aksiale + 2 x 15mm, trans-sinus, 30-35° tilt

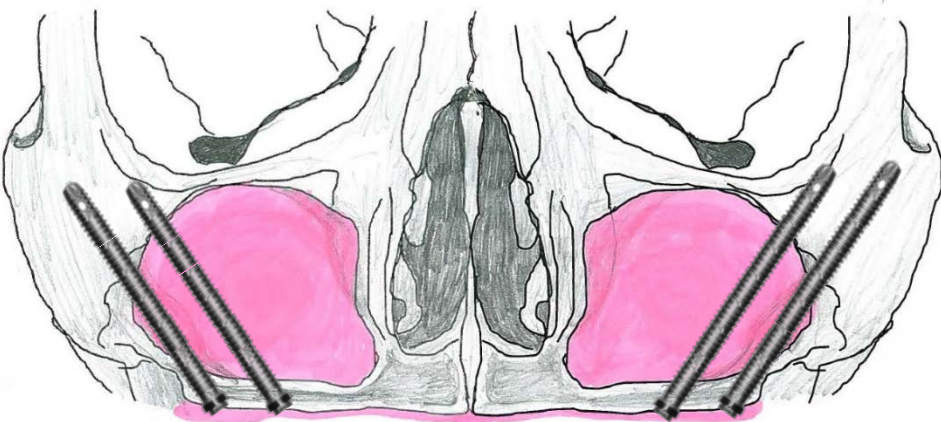
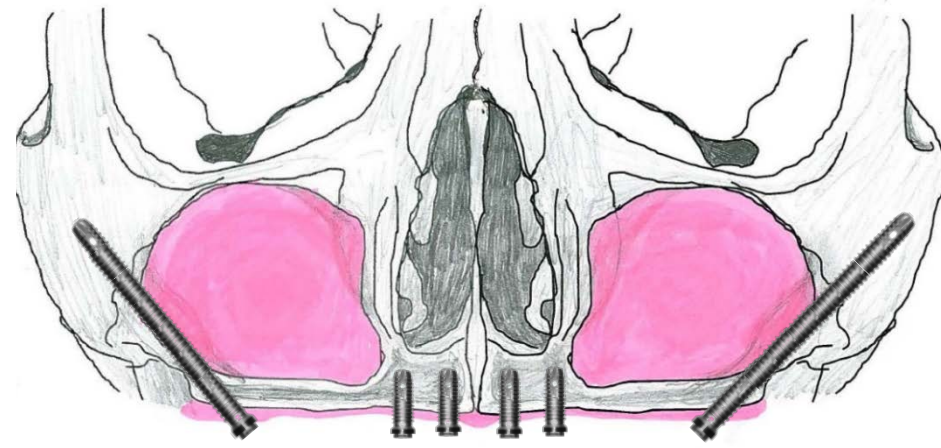
Zygoma implantater

2 trans-sinus Zygoma + f.eks.,
2 vanlige implantater

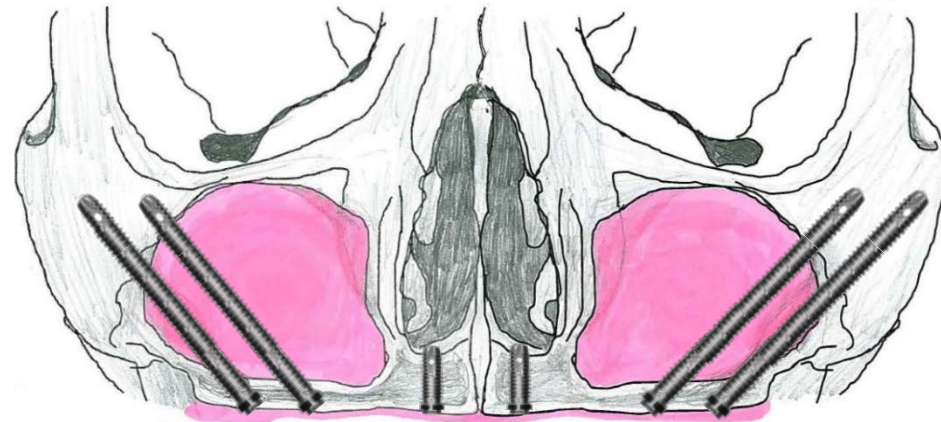

2-4 x 10mm + 2 x 42mm

2 ekstra-sinus Zygoma +,
f.eks., 4 vanlige implantater



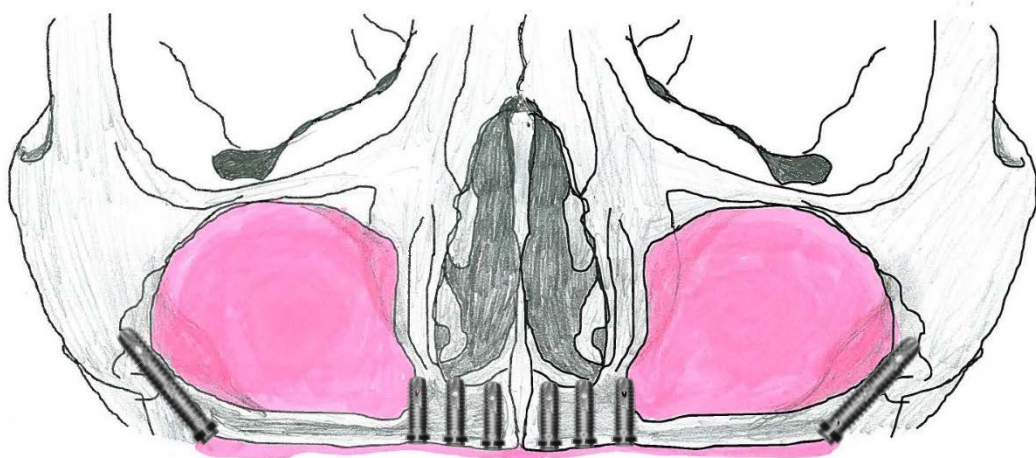
4 trans-sinus Zygoma



4 ekstra-sinus Zygoma implantater

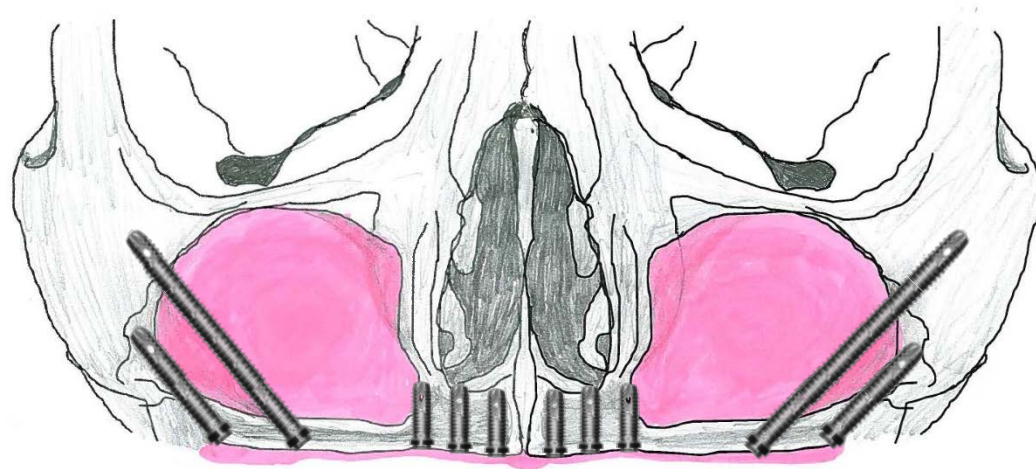
Pterygomaxilla implantater & beinknutepunkt

Hovedsakelig:
Cawood-Howell klasse V / VI



2 pterygomaxilla + 6 vanlige
implantater

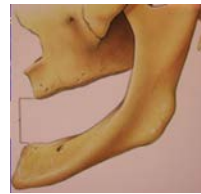vanlige 6 x 10mm
+ pterygoid 2x 15mm



2 Brånemark pterygomaxilla + 6
Brånemark vanlige implantater + 2
Zygoma implantater

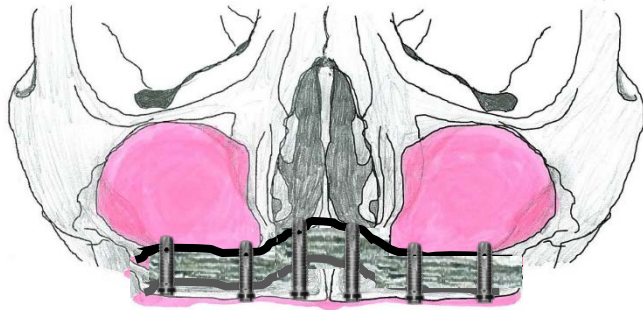
«Teeth-in-an-hour» = 10 implantater
Vanligst er 6 x 10mm
+ 2 pterygoid 15mm
+ 2 Zygoma 42 mm

Beinoppbygging, 1 eller 2 trinn



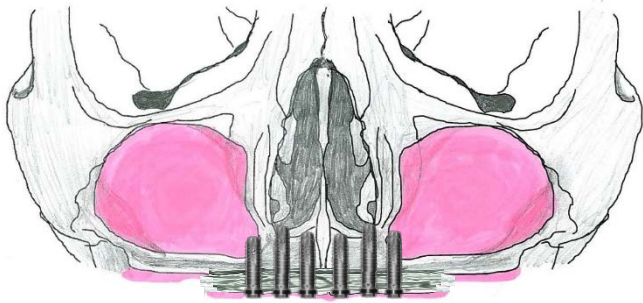Hovedsakelig:
Cawood-Howell klasse VI

Pseudo-klasse III diskrepans som
trenger korreksjon



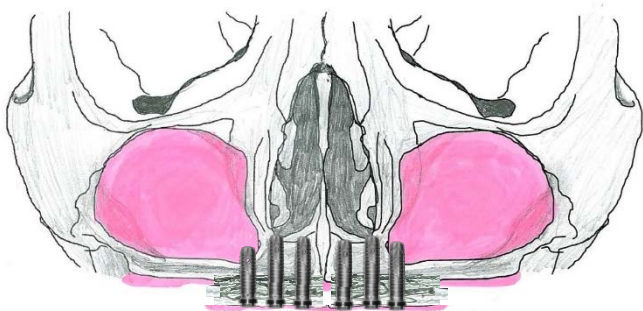
LeFort 1 nedfraktur med interposisjonell
fiksering og implantater plassert
umiddelbart eller etter tilhelning 8-12 mnd.
senere.

6 x 20mm implantater



Fullkjeve onlay blokk med f.eks., 6
implantater plassert umiddelbart

6 x 15/18/20mm implantater

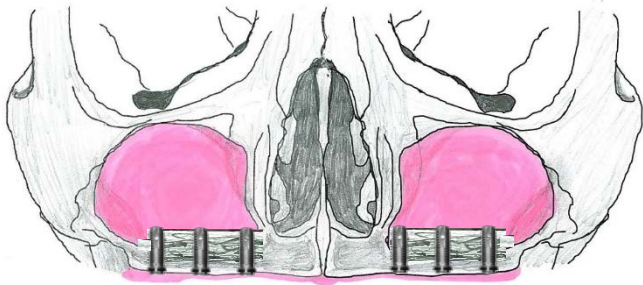


Segmentert blokk onlay med implantater
plassert etter tilhelning 8-12 mnd. senere.

Mest vanlig: Cortico-cancelløs bein fra:
Hoftekam – Kjeve – Tibia - hodeskalle

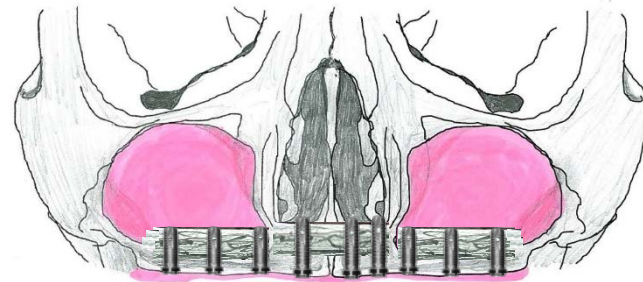
Beinoppbygging, 1 eller 2 trinn

hovedsakelig:
Cawood-Howell klasse VI

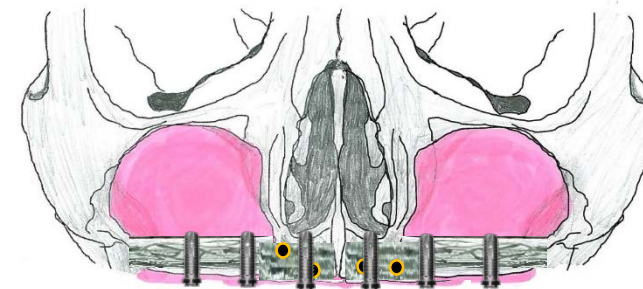


Segmentert inlay blokker i sinus med f.eks
6 implantater plassert umiddelbart

9 x 18mm implantater



Segmentert inlay blokker i sinus og nasalt
med f.eks., 9 implantater plassert
umiddelbart



Segmenterte inlay blokker i sinus +
horisontalle onlay blokk anteriort med
implantater plassert etter tilhelning 4 to 7
mnd. senere